Tuberculosis & the eye

Dr S Gichuhi

Introduction

- Mycobacteria are uncommon causes of ocular disease
- M.tuberculosis
- M.leprae
- Atypical mycobacteria

- Tuberculosis and leprosy are systemic diseases, with ocular involvement (most commonly uveitis) resulting from hematogenous dissemination to the eye.

Pathogenesis

- Infection with *M. tuberculosis* occurs primarily by inhalation of airborne bacilli.
- The number of bacilli necessary to establish infection depends on

  - host immunity, the ability of the organism to multiply within macrophages

  - genetic resistance of the recipient.

Pathogenesis cont.

- In the early stages of infection, alveolar macrophages nonspecifically ingest and either kill or suppress growth of the bacilli.
- After several weeks, delayed-type hypersensitivity to tuberculoprotein causes tubercle formation where caseous necrosis surrounds and destroys the nonactivated macrophages harboring growing bacilli.
- CD4+ T lymphocytes predominate in delayed-type hypersensitivity.
- TNF-α and transforming growth factor-β contribute to the associated tissue damage

Pathogenesis

- Tubercle bacilli can survive but cannot multiply within the anoxic and acidic caseating necrosis.

- Cell-mediated immunity, driven primarily by interferon-γ and other cytokines secreted by activated lymphocytes, helps to destroy any bacilli that escape areas of caseation.

- Both CD4+ (helper) T lymphocytes and CD8+ (suppressor) T lymphocytes are involved.

Tuberculosis

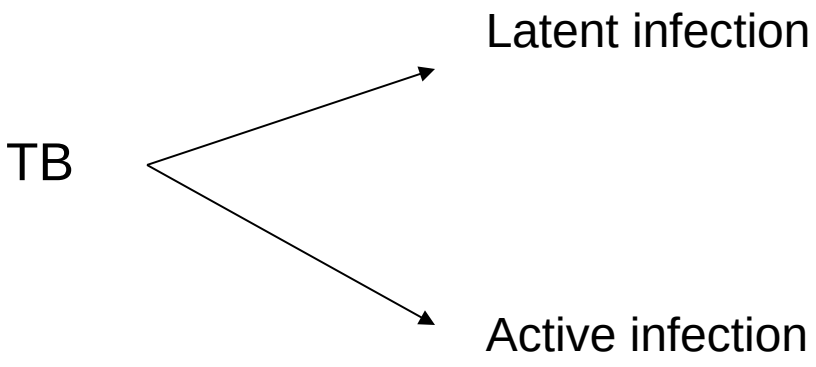

Patterns of TB

(i) Primary TB

- primary infection – lungs - granuloma
- primary disease – caseous breakdown, bacilli released to bloodstream - milliary

(ii) Secondary TB

- reactivation (pulmonary & extrapulmonary

Ocular involvement

- 1-2% of patients with systemic TB
- Mechanisms

  - active infection

  - immunogenic
- Uveitis is the most common manifestation

Active infection

- primary introduction into the eye by

  - contaminated hands or fomites

  - exposure to dust or sputum particles laden with bacilli.
- secondarily by

  - hematogenous spread

  - contiguous spread (e.g., nasal sinuses, meninges).
- Results in granuloma (tubercle) formation that can involve any part of the eye, orbit, or visual pathways.

Immunogenic

- Type IV reaction

Eyelids

- Ulceration
- Lymphadenopathy
- Lupus vulgaris – nodule without lymphadenopathy

  - cicatrization

  - ectropion

Orbit

- cellulitis
- periostitis
- osteomyelitis
- abscess
- chronic dacryoadenitis
- fistula
- dacryocystitis -primary or secondary to adjacent osseous TB.

Conjunctiva

- Rare
- Bulbar nodules
- Conjunctivitis - may start slowly as a granulomatous lesion <u>or</u> present as an acute purulent or pseudomembranous conjunctivitis.
- Parinaud's oculoglandular syndrome – conjunctivitis with visible preauricular or submandibular l-node involvement

Cornea

- allergic origin (phlyctenulosis, interstitial keratitis)
- or secondary to spread from adjacent structures (sclerokeratitis).

Phlyctenulosis

Conjunctival phlycten	Corneal phlycten
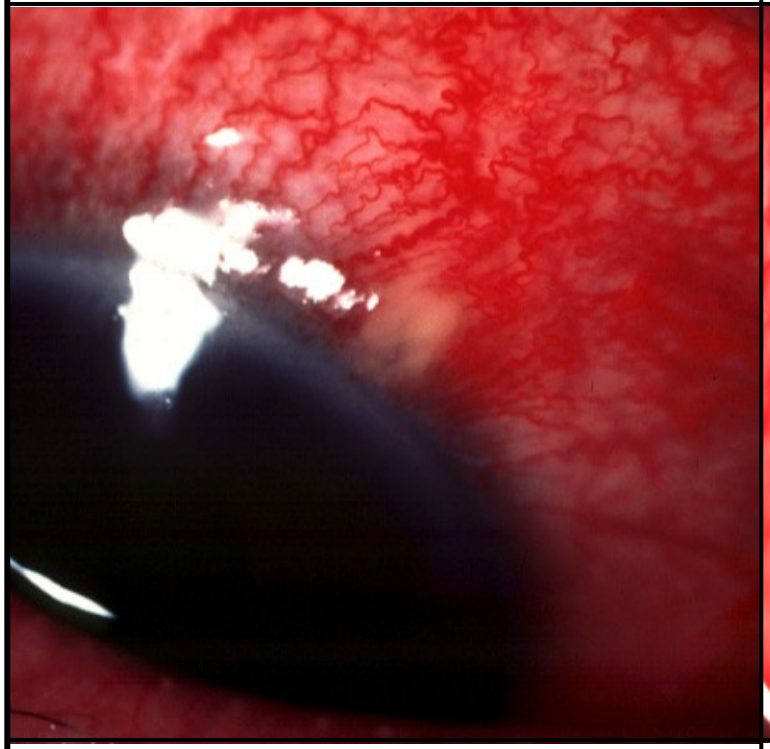	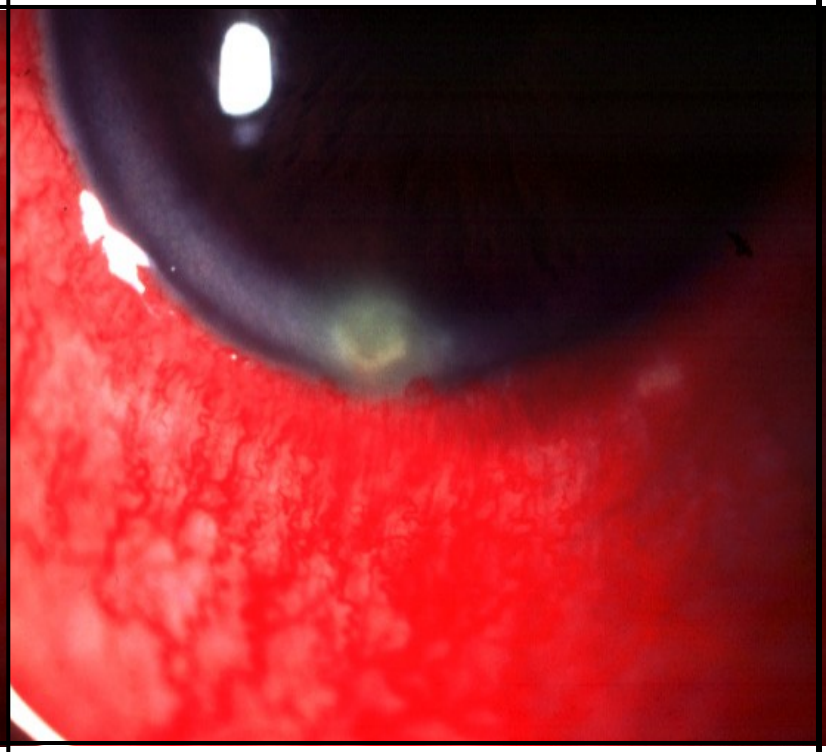
• Small pinkish-white nodule near limbus • Usually transient and resolves spontaneously	• Starts astride limbus • Resolves spontaneously or extends onto cornea

Cornea

- Phlyctenular keratoconjunctivitis is the most common form of external ocular TB

  - caused by tubercle protein hypersensitivity

- Primary infectious keratitis is rare.

- Interstitial keratitis typically affects one eye

  - tuberculoproteins of the cell wall of *M. tuberculosis* cause allergic reactions. Leads to corneal scars.

Sclera & episclera

- Episcleritis
- Deep nodular scleritis

  - from direct invasion by the tubercle bacillus.
  - pain is a prominent feature
  - Eventually, nodule turns yellow as it undergoes caseation, and ulceration follows.
  - Involvement of the adjacent ciliary body and iris can result in an associated granulomatous anterior uveitis.
  - Scleral perforation may occur.
  - poor response to topical corticosteroids, suggesting that the scleritis is the result of direct invasion of the tubercle bacillus and is not a hypersensitivity reaction.

Anterior uveitis

- usually granulomatous, characterized by

  (i) mutton-fat keratic precipitates

  (ii) Koeppe and Busacca nodules on the iris.

  (iii) Hypopyon can occur.

- Less commonly, can be nongranulomatous, with an acute, recurrent, or chronic course.

- Topical corticosteroids may convert an anterior granulomatous uveitis to a nongranulomatous form.

- possibility of TB should be entertained for any steroid nonresponsive uveitis.

Posterior uveitis

- The choroid has a particular propensity for involvement by TB.
- Choroidal granulomas can be solitary or—as in miliary TB—multiple, causing a disseminated choroiditis.
- Choroidal granulomas are yellowish-white nodules with indistinct borders, diameter 0.5 mm to 2 cm. They may be seen in patients without active systemic disease

Tuberculous uveitis

Chronic granulomatous iridocyclitis

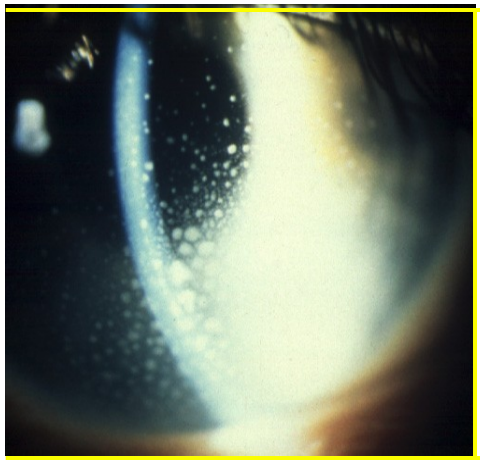

Mutton fat KP

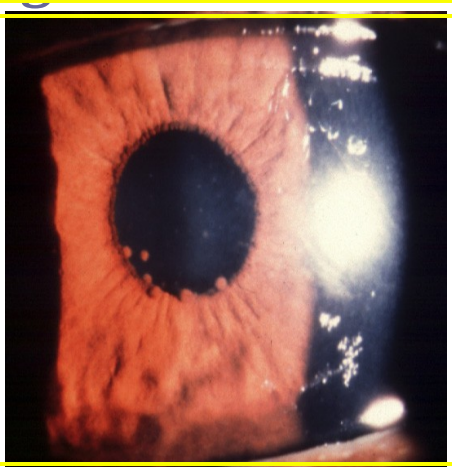

Koeppe nodules

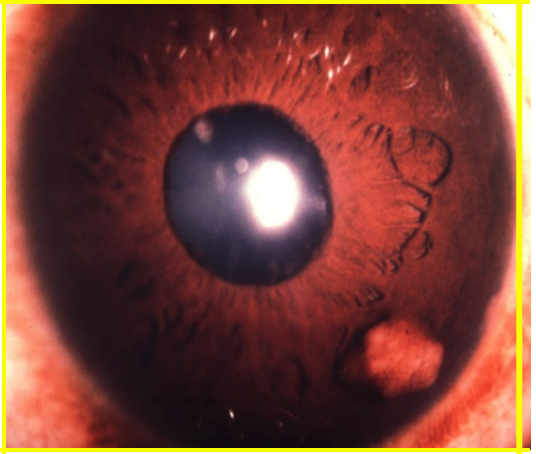

Busacca nodules

Posterior uveitis

Choroiditis - unifocal or multifocal

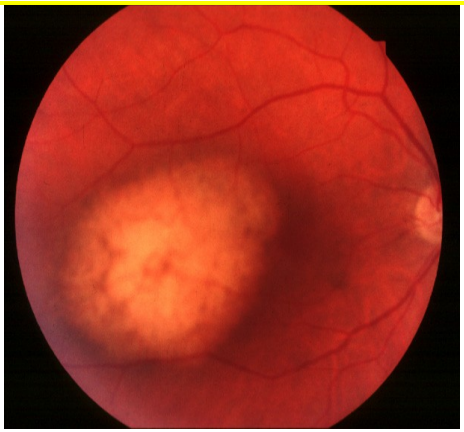

Large solitary choroidal granuloma

Retinal periphlebitis

Latent choroidal tubercle in a patient with multidrug resistant TB.

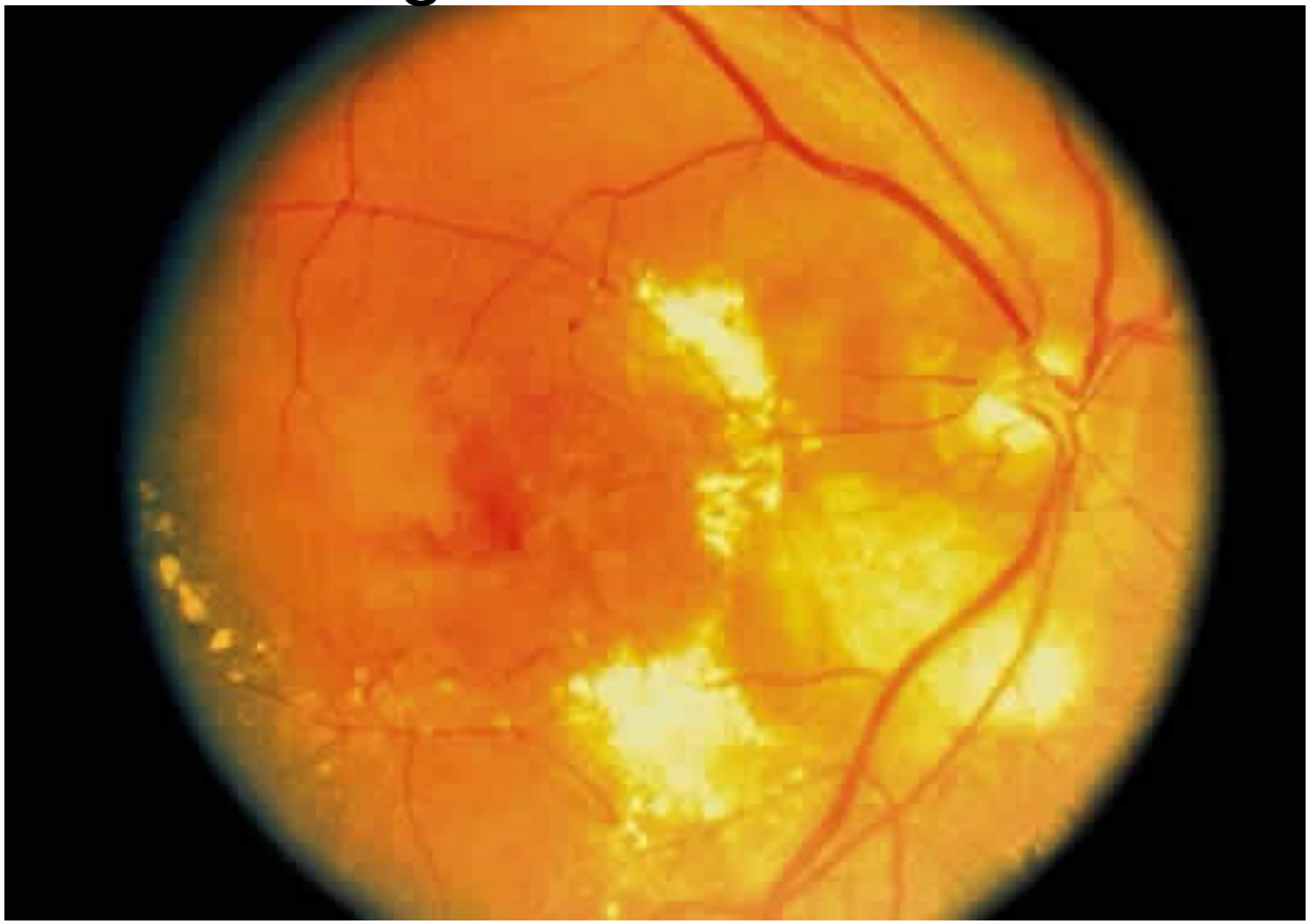

Retina

- endogenous spread from a distant source
- may take two forms:

  - In the miliary type, small localized tubercles that eventually heal (superficial exudative retinitis).

  - massive retinitis with extensive grey-white lesions and heavy vitreous reaction. Severe endophthalmitis can ensue.
- Neuroretinitis

Optic nerve involvement

- may accompany uveitis or tuberculous meningitis

  - either unilaterally as a direct infiltration of the nerve (inflammatory disc edema)

  - or bilaterally because of increased intracranial pressure (papilledema).

- optic atrophy after TB meningitis

  - addition of dexamethasone to the treatment of tuberculous meningitis may help prevent optic atrophy.

- Optic neuropathy also may occur as a result of antituberculous treatment with ethambutol and INH.

CNS involvement

- Tuberculous meningitis typically causes a basilar meningitis and may involve any of the cranial nerves.
- multiple cranial nerve involvement.
- Alternatively, disease within CNS may lead to focal cranial mononeuropathies or other neuroophthalmic syndromes, such as

  - internuclear ophthalmoplegia

  - bilateral internuclear ophthalmoplegia

  - chiasmal or junctional visual loss,

  - gaze palsy

  - III cranial nerve palsy
- tuberculoma may behave as a SOL